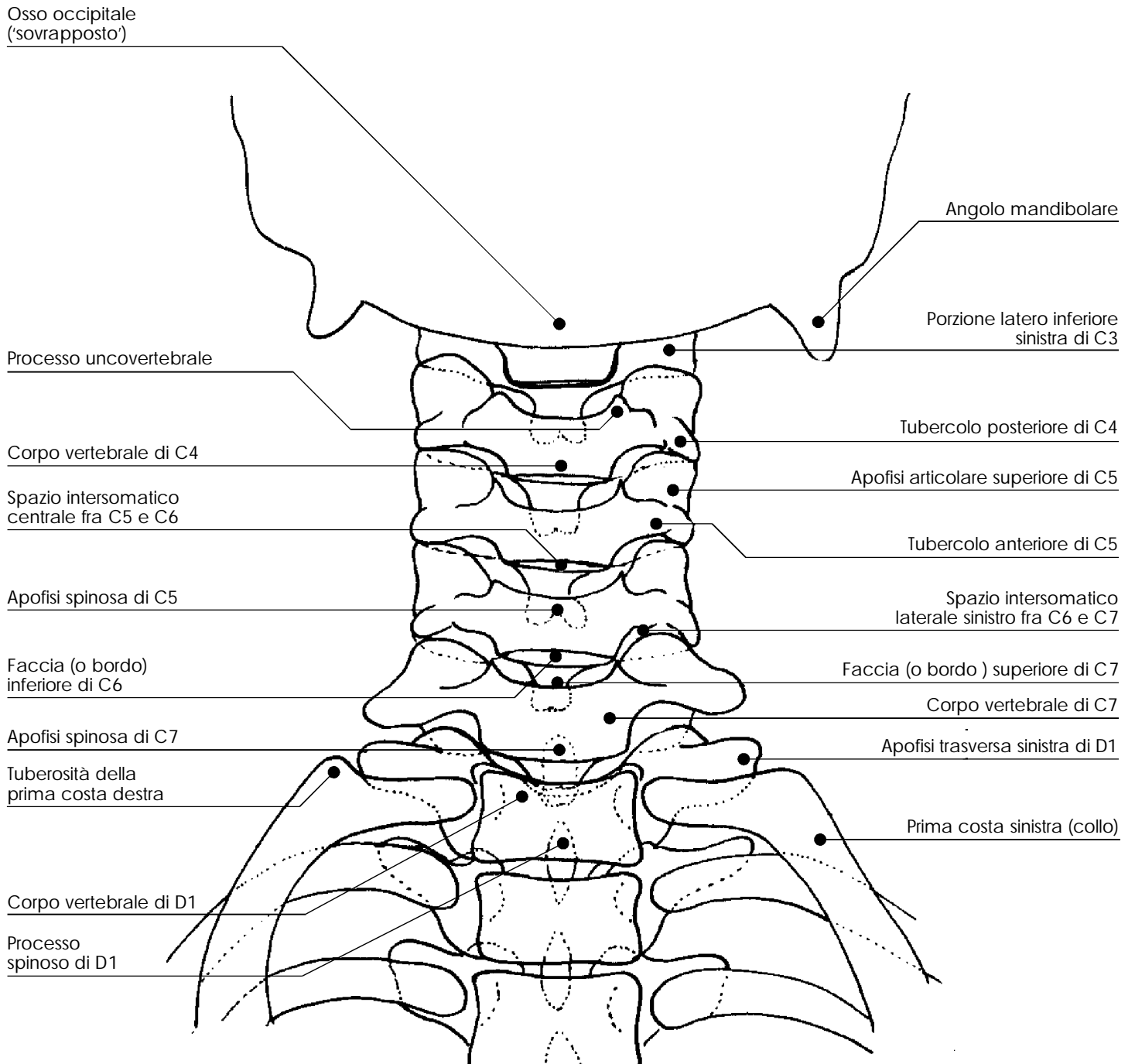
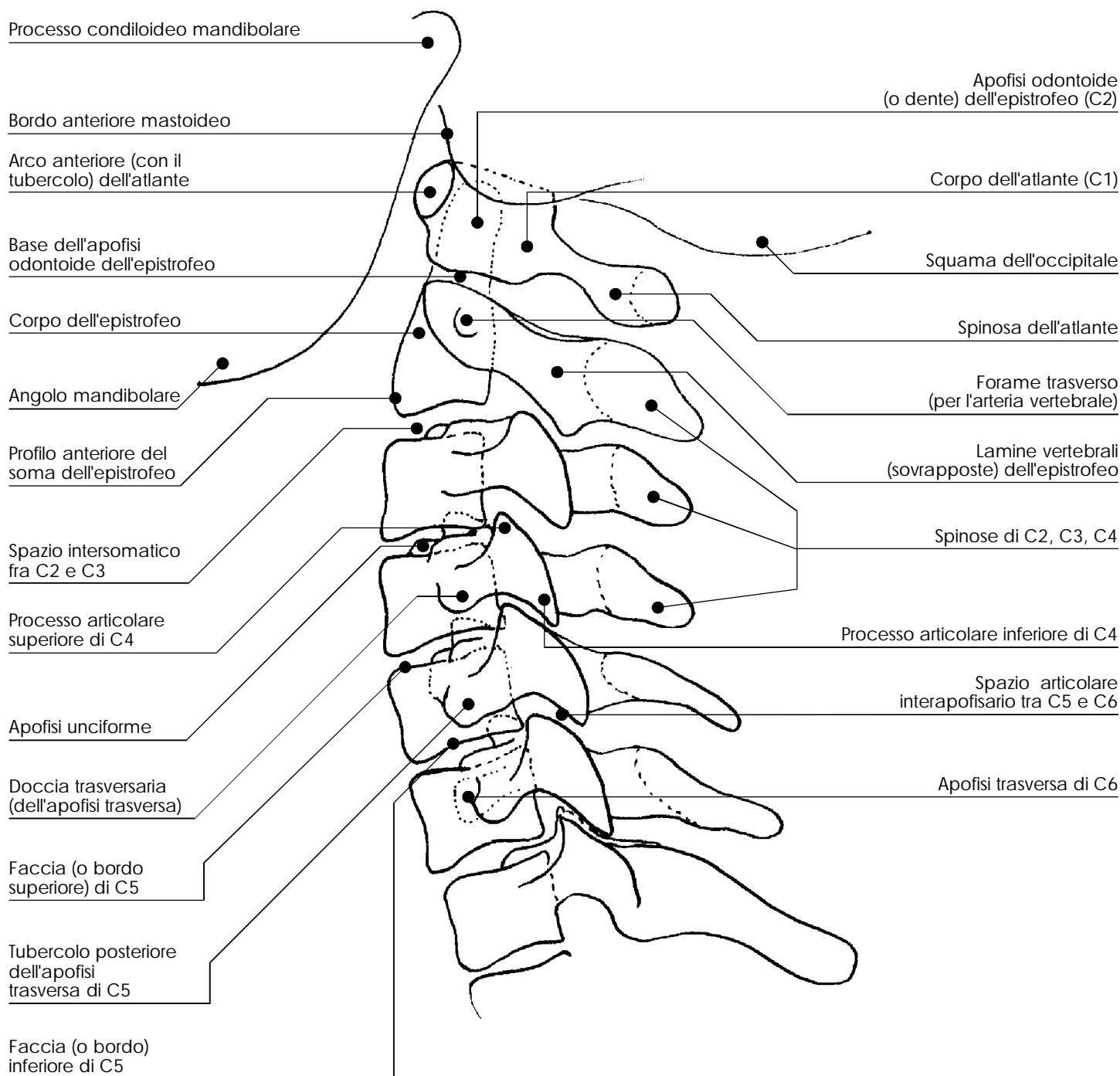


rachide cervicale

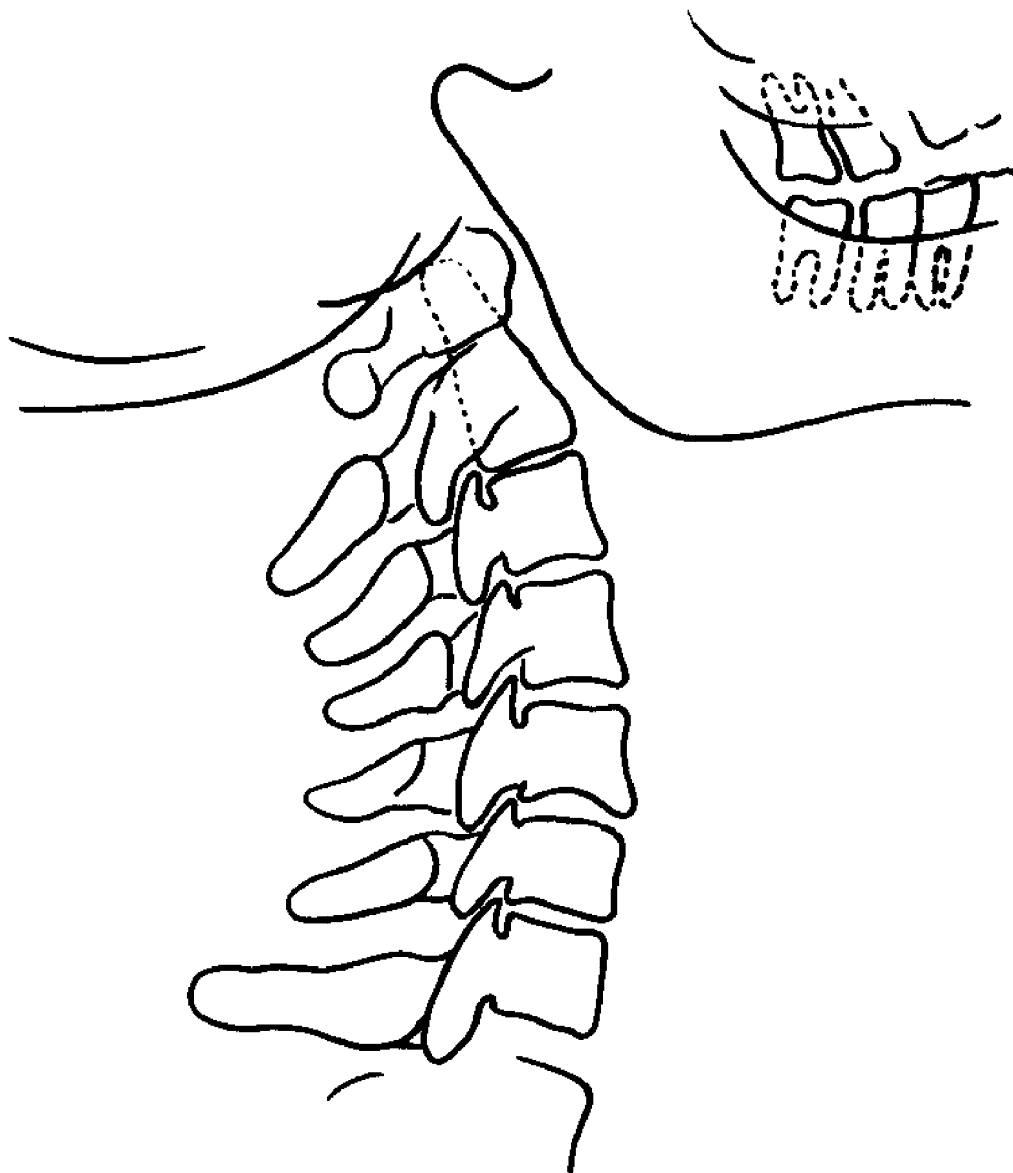


rachide cervicale



rachide cervicale

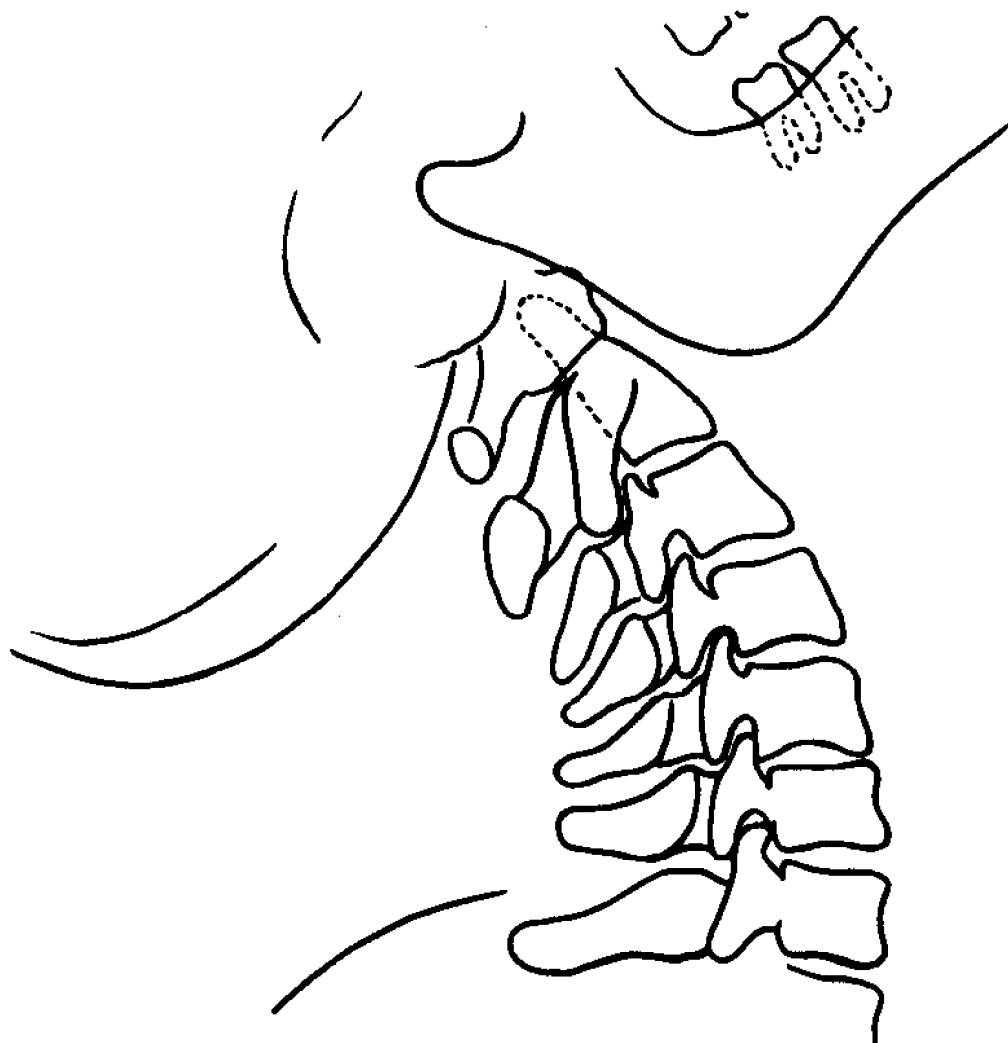
Radiogramma a riposo



PROIEZIONE LATERO-LATERALE

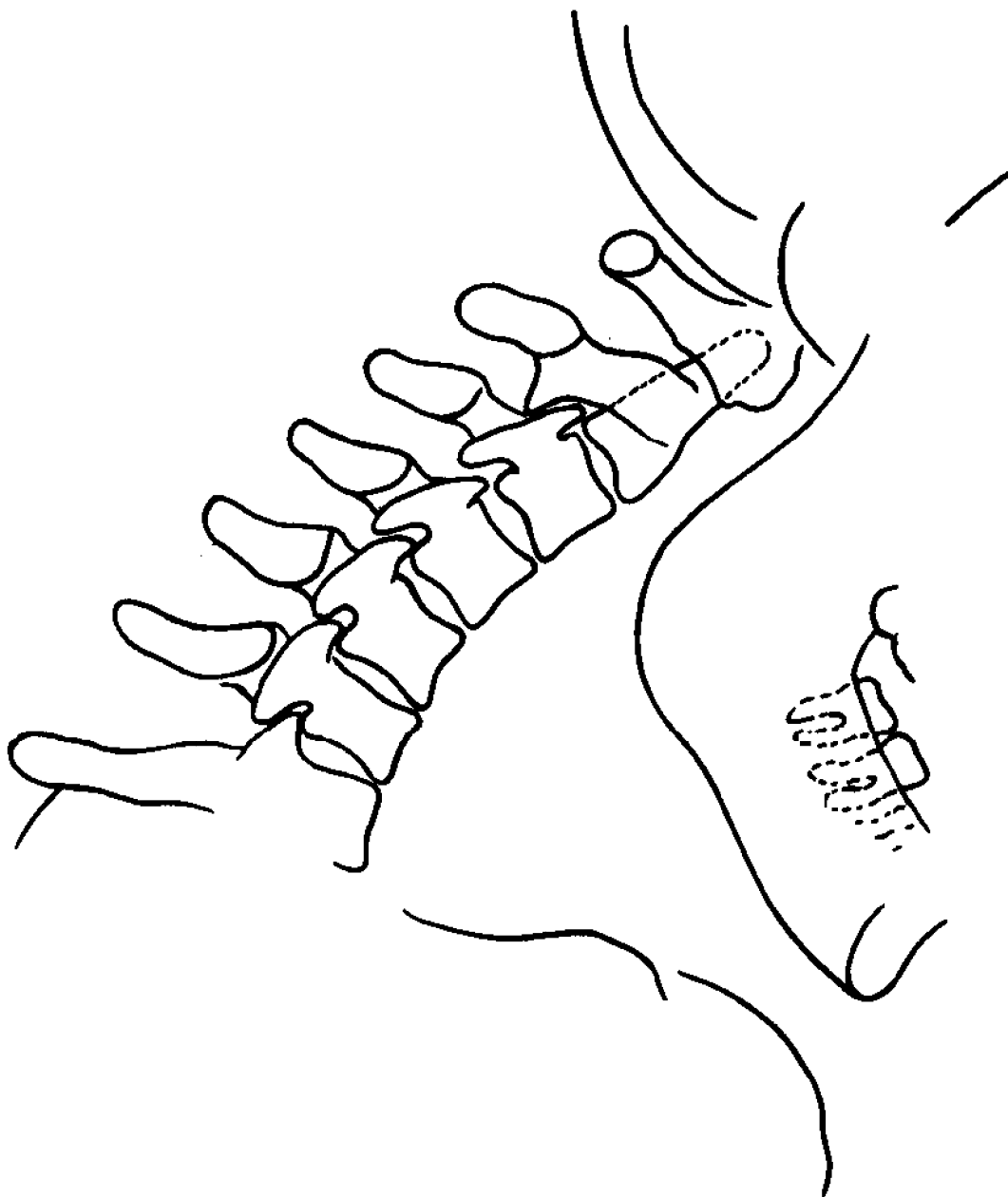
rachide cervicale

Radiogramma in iperestensione (iperlordosi). Le apofisi si ravvicinano e si riduce l'ampiezza degli spazi interarticolare apofisari

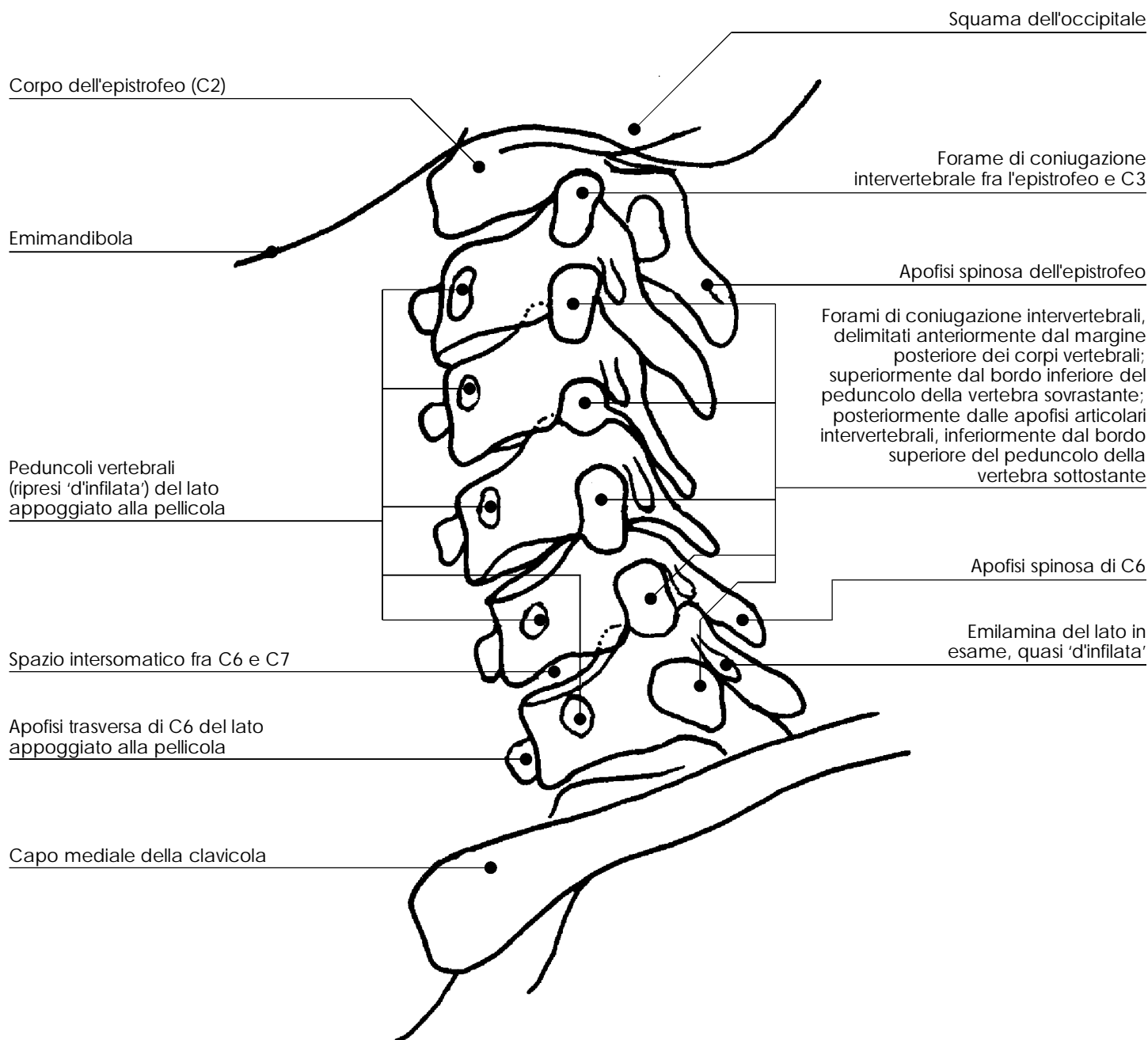


rachide cervicale

Radiogramma in iperflessione
Si riduce, o scompare, la fisiologica
lordosi, fino a lieve cifosi e le apofisi
spinose tendono a distanziarsi fra loro



rachide cervicale



rachide cervicale

